

PATIENT PRESENTING CLINICAL SIGNS

Lilo Lloret Patient presents for CT chest evaluation for possible pulmonary nodule. Pre-anesthesia radiographs were performed, and the following findings were observed: a 1 cm x 1 cm soft tissue opacity within the hilus of the caudal subset of the left cranial lung lobe. Interpretation by radiologist: consider pulmonary nodule within the hilus of the left cranial lung lobe.

SPECIES

Canine Abnormal PE/Chem/CBC/UA Results: CBC --- unremarkable CHEM --- BUN/CREA Ratio increased (34), Calcium increased (8.8)

COMPUTED TOMOGRAPHIC STUDY OF THE THORAX

BREED

Dachshund

Plain and post contrast studies are available for review.

COMPUTED TOMOGRAPHIC FINDINGS

SEX

The bony and surrounding soft tissue structures are within normal limits.

MN

The sternal, cranial mediastinal and tracheobronchial lymph nodes are small elongated with a normal short-to-long-axis-ratio is < 0.5, the attenuation and contrast enhancement pattern are uniform and considered within normal limits.

AGE

The cardiovascular structures, including the pulmonary vasculature are within normal limits.

8yr

Small incidental gas pockets are seen within the esophageal lumen; there is no evidence of abnormal dilation.

INTERPRETED BY

Nele Eley (Ondreka),
DVM Dr. med. vet.,
DipECVDI

No pulmonary nodules, masses or other focal pulmonary lesions are identified. The described radiographic soft tissue opacity is likely to correspond to the anatomic course and end on summation of the left main pulmonary artery within the hilar region, which can mimic a nodule on radiographs, especially on lateral views. The pulmonary parenchyma is otherwise unremarkable. No evidence of pulmonary infiltrates, consolidations, cavitary lesions, pleural effusion of pneumothorax is identified.

HOSPITAL NAME

Veterinary Image
Center

COMPUTED TOMOGRAPHIC DIAGNOSIS

- No evidence of pulmonary nodules or masses, suspect summation/ end on projection of the left main pulmonary artery in the hilar region on prior radiographs.
- No significant thoracic abnormalities identified on CT examination.

REFERRING VET

Roberto Vega DVM

INTERPRETATION OF FINDINGS & FURTHER RECOMMENDATIONS

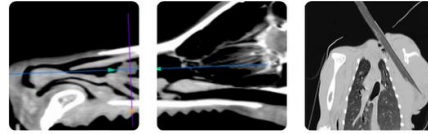
INVOICE

24892

The CT study reveals no evidence of a pulmonary nodule. No intrathoracic mass lesion is identified. The radiographic opacity of concern is likely attributable to the normal left main pulmonary artery viewed in projection within the hilar region, creating a summation effect that mimics a pulmonary nodule on radiographs. This represents a benign radiographic superimposition artifact rather than true pulmonary pathology.

DATE

05/20/2026



PATIENT

Lilo Lloret

SPECIES

Canine

BREED

Dachshund

SEX

MN

AGE

8yr

INTERPRETED BY

Nele Eley (Ondreka),
DVM Dr. med. vet.,
DipECVDI

HOSPITAL NAME

Veterinary Image
Center

REFERRING VET

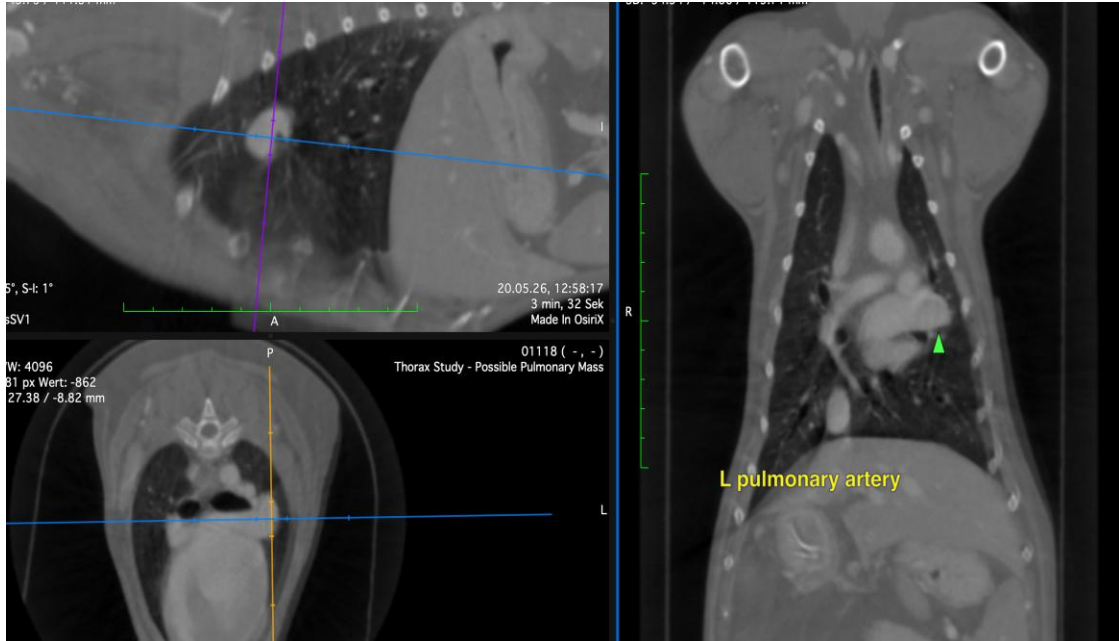
Roberto Vega DVM

INVOICE

24892

DATE

05/20/2026



The information and recommendations provided are based on the images presented by the referring veterinarian. No evaluation can be communicated regarding pathology that was not visible in the image/video clips provided.

Thank you for this referral. If the clinical or image interpretation does not parallel your findings or if I can be of any further assistance please contact me.

Nele Eley (Ondreka), DVM, Dr. med. vet., DipECVDI
European Specialist in Veterinary Diagnostic Imaging, Cert. Radiology,
Senior lecturer University of Giessen/Germany, Veterinary Faculty, Department of Radiology.
info@sonopath.com